

10-2018

A case of Dandy-Walker Syndrome

Stanlies D'Souza

Baystate Health, dsouzastan@yahoo.com

Follow this and additional works at: https://scholarlycommons.libraryinfo.bhs.org/all_works



Part of the [Medicine and Health Sciences Commons](#)

Recommended Citation

D'Souza S. A case of Dandy-Walker Syndrome . American Society of Anesthesiologists (ASA) Conference, October 13-17, 2018, San Francisco, CA.

This Presentations, Research is brought to you for free and open access by Scholarly Commons @ Baystate Health. It has been accepted for inclusion in All Scholarly Works by an authorized administrator of Scholarly Commons @ Baystate Health.

INTRODUCTION

Dandy-Walker Malformation (DWM) is a congenital anomaly of the cerebellum and fourth ventricle characterized by hypoplasia of the cerebellum and hydrocephalus secondary to cystic expansion within the fourth ventricle.

Such malformations commonly result in increased intracranial pressure from hydrocephalus and facial anatomical distortions such as cleft lip/palate, hyperterlorism and micrognathia making airway management challenging.

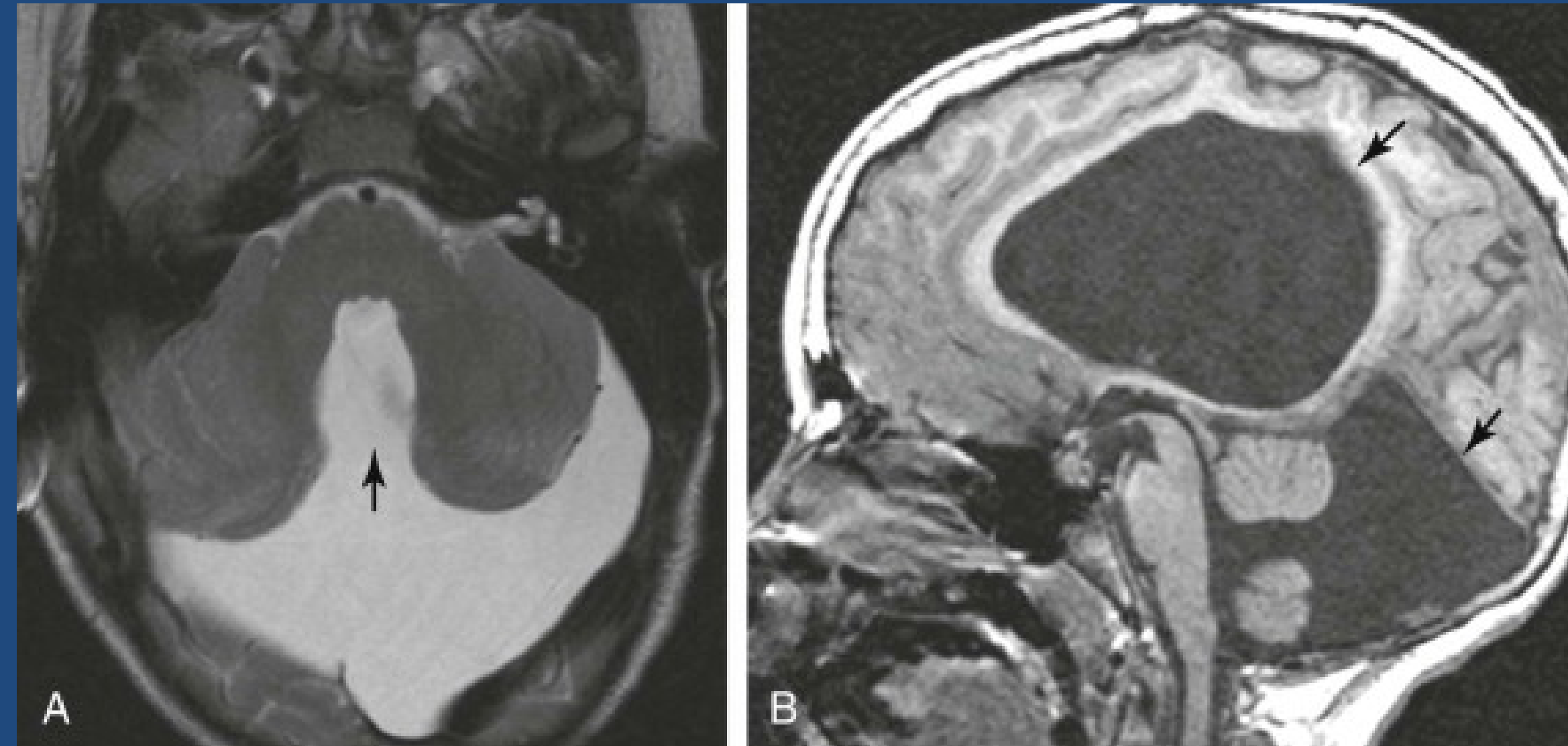


Figure 1. Dandy-Walker Malformation with Enlargement of Posterior Fossa. A) T2 Weighted MRI. Absence of cerebellar vermis (arrow). B) T1 weighted MRI. Elevation tentorium (bottom arrow) and Hydrocephalus.⁷ Image obtained from Clinical Key

CASE DESCRIPTION

A 10-year-old female with bilateral congenital talipes equinovarus and developmental delay secondary to underlying DWM who had shunted hydrocephalus in infancy presented for left foot osteotomy, calcaneocuboid fusion, and heel cord lengthening for recurrent left foot deformity.

After inhalational induction and placement of an intravenous line, airway was managed with a laryngeal mask airway (LMA). The perioperative course was uneventful.

Table 1: Clinical Aspects of Dandy Walker Syndrome^{1,2}

Obstructive Hydrocephalus	• Cranial nerve palsies
Raised intracranial pressure	• Irritability • Vomiting • Convulsions
Cerebellar signs	• Ataxia • Nystagmus
Agenesis of Corpus Callosum	• Developmental delay/Mental retardation • Medullary failure (respiratory regulation)
Seizures	

Table 2: Extracerebral Anomalies^{1,2}

✓ Cleft palate	✓ Congenital heart defects (VSD)
✓ Micrognathia	✓ Renal abnormalities
✓ Eye abnormalities (increased intraocular pressure)	✓ Infundibular hematomas
✓ Skeletal abnormalities (lumbar vertebrae)	✓ Posterior fossa lymphomas
✓ Polydactyly	✓ Syringomyelia

DISCUSSION

Dandy-Walker Malformation is a heterogeneous and in some cases auto recessive inheritance. Incidence of 1:25,000 newborns.¹ Affected children with hydrocephalus often present with bulging fontanelles and occiput, congenital neurodevelopmental and craniofacial anomalies.^{1,2} Therefore, patients with DWM often can present with potential challenging airway management requiring advance airway equipment preparation at bedside, such as rigid or flexible fiberoptic airway equipment.

A major concern in a patient with DWM is intracranial pressure (ICP) management. Endotracheal intubation should be done as gentle as possible. An LMA was used in our case to avoid increased sympathetic response from intubation. The use of succinylcholine is also often avoided as it has the potential to increase ICP. Inhalational agents cause a dose dependent rise in ICP, however isoflurane and sevoflurane <1 MAC concentration do not cause a significant rise in ICP. In addition, hypercarbia results in an increase in cerebral flow and as a result elevates ICP.²⁻⁵ End tidal CO₂ should be maintained at 30-35mmHg.

In addition to the 4th ventricle and cerebellum abnormalities, agenesis of Corpus Callosum in DWM patients increases their likelihood of apnea and respiratory failure.⁴ Confirm adequate oxygenation and ventilation prior to extubation. Precautions must be taken for post-operative respiratory decompensation.

CONCLUSION

Dandy-Walker Malformations are often associated with craniofacial abnormalities, elevated ICP, post-operative respiratory complications that could cause challenges in anesthetic management

Key to successful anesthetic management in these patients are careful assessment of airway anatomy with appropriate plan for difficult airway, ICP control and attentive post-operative care monitoring.

REFERENCES

- Bissonnette B, Luginbuehl I, Marciniak, Dalens B. Syndromes: Rapid Recognition and Perioperative Implications. Dandy-Walker Malformation. McGraw-Hill Global Education Holdings, LLC. 2006 USA. McGraw-Hill Global Education Holdings, LLC. © 2006.
- Kulkarni S, Kelkar V, Ruhatiya* S. Anesthetic Management of an Adolescent with Dandy Walker Malformation. Case Report. International Journal of Current Medical and Applied Sciences. Vol. 3. Issues: 2014:07-09 Copyright @ 2014 Logic Publications, IJCMAS, E-ISSN:2321-9335, P-ISSN:2321-9327.
- Jang JS, Lee JJ, Park WJ, et.al. Anesthetic Management of an Adolescent with Dandy-Walker Syndrome. Case Report. Korean Journal of Anesthesiol. Web. 6 Sept. 2018. 2013 Feb;64(2):180-1. doi: 10.4097/kjae.2013.64.2.180. Epub 2013 Feb 15.
- Woodward T. Anesthetic Management for a Patient with Dandy-Walker Syndrome. Westminster College Utah. Dec. 2014 cdmuntu.lib.utah.edu/utills/getfile/collection/wc-ir/id/121/filename/123.pdf
- Singh R, Dogra N, Jain P, et al. Dandy Walker Syndrome with Giant Occipital Meningocele with Craniovertebral Anomalies: Challenges Faced during Anaesthesia. Letter to Editor. Indian Journal of Anaesthesia. 2016;Vol 60. (1):71-73
- Datt V, Tempe D K, Lalwani P, Aggarwal S, Kumar P, Diwakar A, Tomar A S. Perioperative management of a patient with Dandy Walker malformation with tetralogy of Fallot undergoing total correction and fresh homologous pericardial pulmonary valve conduit implantation: Report of a rare case. Ann Card Anaesth 2015;Vol18.(3) 433-436
- Gressens P, Huppi PS. Chapter 58, Normal and Abnormal Brain Development. Dandy-Walker Malformation. In: Martin's Neonatal-Perinatal Medicine. 10th ed. Elsevier-Saunders, Philadelphia, PA. 2015 Figure 58-25. Image courtesy of J. Delavelle, Department of Radiology, University Hospitals of Geneva, Geneva, Switzerland.